

Standards for acquiring digital chest radiography images for medical surveillance of Queensland coal mine workers

Including technical quality grading guidelines for ILO classifications

SEPTEMBER 2017



This publication has been compiled by Coal Mine Workers' Health Scheme of Minerals and Energy Resources Division, Department of Natural Resources and Mines.

© State of Queensland, 2017

The Queensland Government supports and encourages the dissemination and exchange of its information. The copyright in this publication is licensed under a Creative Commons Attribution 4.0 International (CC BY 4.0) licence.

Under this licence you are free, without having to seek our permission, to use this publication in accordance with the licence terms.



You must keep intact the copyright notice and attribute the State of Queensland as the source of the publication.

Note: Some content in this publication may have different licence terms as indicated.

For more information on this licence, visit <https://creativecommons.org/licenses/by/4.0/>.

The information contained herein is subject to change without notice. The Queensland Government shall not be liable for technical or other errors or omissions contained herein. The reader/user accepts all risks and responsibility for losses, damages, costs and other consequences resulting directly or indirectly from using this information.

Table of contents

Acknowledgement	1
Introduction	1
Background	1
Purpose	2
Acronyms and abbreviations	3
Part 1: Standards	4
1. Government regulation	4
2. RANZCR and DIAS standards.....	4
3. Personnel	4
Medical physicists	4
Radiographers	4
4. Imaging equipment and software.....	5
Imaging equipment	5
Image capture hardware and software	5
Image manipulation.....	5
Image data file	5
5. Image acquisition	6
Beam lighting devices	6
Equipment specifications	6
Image quality.....	6
6. Documentation	7
7. Quality assurance and control	7
Part 2: Technical guidelines for taking chest X-rays	8
Grading images.....	8
Common difficulties.....	9
Scapula overlay	9
Excessive edge enhancement.....	9
Chest wall variations	9
Examples of images and interpretation	10
References	21

List of images

Image A – ILO Classification form section 1	8
Image 1 – Chest X-ray 1	10
Image 2 – Chest X-ray 2	11

Image 3 – Chest X-ray 3	12
Image 4 – Chest X-ray 4	13
Image 5 – Chest X-ray 5	14
Image 5a – CT scan	15
Image 6 – Chest X-ray 6	16
Image 7 – Chest X-ray 7	17
Image 8 – Chest X-ray 8	18
Image 9 – Chest X-ray 9	19
Image 10 – Chest X-ray 10	20

List of tables

Table A: Technical grading	8
Table 1 – Interpretation of chest X-ray 1	10
Table 2 – Interpretation of chest X-ray 2	11
Table 3: Interpretation of chest X-ray 3	12
Table 4: Interpretation of chest X-ray 4	13
Table 5: Interpretation of chest X-ray 5	14
Table 6: Interpretation of chest X-ray 6	16
Table 7: Interpretation of chest X-ray 7	17
Table 8: Interpretation of chest X-ray 8	18
Table 9: Interpretation of chest X-ray 9	19
Table 10: Interpretation of chest X-ray 10	20

Acknowledgement

These standards and guidelines have been developed in consultation with Australian and international experts in chest X-ray screening for pneumoconiosis and radiology including:

- Professor Robert Cohen MD, FCCP, B-Reader, Clinical Professor of Environmental and Occupational Health Sciences, University of Illinois at Chicago School of Public Health
- Dr Katrina Newbigin, FRANZCR, B-Reader, RANZCR Register of Clinical Radiologists for CWP Screening
- Dr Nigel Sommerfeld, FRANZCR, RANZCR Register of Clinical Radiologists for CWP Screening
- Dr Janet Gray, FRANZCR, State Radiologist, BreastScreen Queensland.

Introduction

Background

The Coal Mine Workers' Health Scheme (the Scheme) aims to protect the health of Queensland coal mine workers by ensuring they undergo compulsory health assessments. A chest X-ray examination is a key component of the health assessment. Careful examination of high quality chest X-rays is crucial to detecting small opacities indicative of early dust lung diseases.¹

In 2016, the Monash University Centre for Occupational and Environmental Health in collaboration with the School of Public Health at the University of Illinois at Chicago, reviewed the respiratory component of the Coal Mine Workers' Health Scheme² (Monash review). The Monash review identified a number of issues with the Scheme, including the chest X-ray screening component. In particular, the review found a higher than acceptable portion of chest X-ray images had quality issues which could affect the accurate detection of small opacities characteristic of coal workers' pneumoconiosis (CWP).

The Monash review recommended guidelines be provided to radiology practices performing chest X-rays for the Scheme detailing the appropriate qualification of personnel, imaging equipment and software, image acquisition, documentation, image display and quality control systems.³

This document delivers this Monash review recommendation by providing standards based on the National Institute for Occupational Safety and Health (NIOSH) *Guideline for the Application of Digital Radiography for the Detection and Classification of Pneumoconiosis*⁴ adapted for use in Australia.

This document also includes a guideline on the use of the technical quality grading scale under the International Labour Organization (ILO) *Guidelines for the use of the ILO International Classification of Radiographs of Pneumoconioses*⁵.

¹ Monash review p18.

² Monash review - https://www.dnrm.qld.gov.au/_data/assets/pdf_file/0009/383940/monash-qcwp-final-report-2016.pdf

³ Refer to recommendation 11.5 of the Monash review.

⁴ NIOSH Guideline - <https://www.cdc.gov/niosh/docs/2011-198/>

⁵ ILO Classification - http://www.ilo.org/wcmsp5/groups/public/---ed_protect/---protrav/---safework/documents/publication/wcms_168260.pdf

Purpose

This document has two parts. Part 1 details the standards for radiology practices and personnel involved in acquiring digital chest X-ray images for coal mine workers. The objective of the standards is to identify requirements and highlight existing Australian standards that are considered important in generating high quality digital chest radiography images for the purpose of detecting pneumoconiosis.

Part 2 provides guidance on the technical grading of images under the ILO International Classification of Radiographs of Pneumoconioses 2011D (ILO Classification). As of 1 January 2017, all chest X-rays taken under the Scheme must be performed in accordance with the ILO Classification. The guideline in this document seeks to inform practices how chest X-rays are graded under the Scheme and the associated technical issues that can reduce image quality for the purposes of reporting images to the ILO Classification.

Acronyms and abbreviations

ACPSEM	Australasian College of Physical Scientists and Engineers in Medicine
AHPRA	Australian Health Practitioner Regulation Agency
CMWHS	Coal Mine Workers' Health Scheme
CR	Computed radiography
CWP	Coal workers' pneumoconiosis
DIAS	Diagnostic Imaging Accreditation Scheme
DICOM®	Digital Imaging and Communications in Medicine
DR	Digital radiography
ILO	International Labour Organization
NIOSH	National Institute for Occupational Safety and Health
PA	Postero-anterior
RANZCR	Royal Australian and New Zealand College of Radiologists

Part 1: Standards

1. Government regulation

- 1.1 Radiology practices involved in acquiring digital chest X-ray images for coal mine workers are required to comply with all relevant State or Territory and Commonwealth legislation.

2. RANZCR and DIAS standards

Radiology practices and the personnel involved in acquiring digital chest X-ray images for coal mine workers are required to:

- 2.1 Comply with the Royal Australian and New Zealand College of Radiologists' (RANZCR) Standards of Practice for Diagnostic and Interventional Radiology⁶.
- 2.2 Comply with the Diagnostic Imaging Accreditation Scheme's (DIAS) Practice Accreditation Standards⁷.
- 2.3 Be accredited with the Diagnostic Imaging Accreditation Scheme⁸.

3. Personnel

Medical physicists

Medical physicists involved in diagnostic imaging services for coal mine workers, including auditing and servicing systems and equipment, shall meet the following requirements:

- 3.1 Registered on the ACPSEM Register of Qualified Medical Physics Specialists in the Radiology Medical Physics Specialty.
- 3.2 Licenced by the relevant State or Territory radiation regulator to use radiation apparatus in their capacity as medical physicists.

Radiographers

Radiographers acquiring digital chest X-ray images for coal mine workers shall meet the following requirements:

- 3.3 Registered as a medical radiation practitioner with the Australian Health Practitioner Regulation Agency (AHPRA).
- 3.4 Possess a current radiation use licence for the State or Territory within which the radiographer practices.

⁶ RANZCR Standard of Practice - <https://www.ranzcr.com/search?searchword=standard+of+practice>

⁷ DIAS Practice Accreditation Standards -

[http://www.health.gov.au/internet/main/publishing.nsf/Content/DCC9E1DB6C39C2CFCA257E92000AE255/\\$File/Practice%20Accreditation%20Standards%20-%20from%201%20January%202016.pdf](http://www.health.gov.au/internet/main/publishing.nsf/Content/DCC9E1DB6C39C2CFCA257E92000AE255/$File/Practice%20Accreditation%20Standards%20-%20from%201%20January%202016.pdf)

⁸ DIAS accreditation - <http://www.health.gov.au/internet/main/publishing.nsf/Content/di-quality>

4. Imaging equipment and software

- 4.1 Medical imaging clinics providing services to coal mine workers shall ensure its equipment and software meet the requirements below in addition to the RANZCR Standards of Practice and the DIAS Practice Accreditation Standards.

Imaging equipment

- 4.2 Only CR or DR imaging equipment to be used.
- 4.3 The equipment shall qualify for 100% of the Medicare Benefits Schedule fee under the Australian Government's Capital Sensitivity program⁹.
- 4.4 Equipment should meet testing as required by State or Territory radiation licencing.
- 4.5 Focal spot should be no larger than 2.0 millimetres (mm).

Image capture hardware and software

- 4.6 Imaging plate should be a minimum of 35x43 centimetres (cm) or 1505 cm², maximum pixel pitch of 200 micrometres (µm), minimum matrix size of 3.75 megapixels (MP), and minimum bit depth of 10.
- 4.7 Spatial resolution should be at least 2.5 line pairs per mm in both vertical and horizontal directions measured at the image receptor.
- 4.8 Detectors and image plates must undergo routine cleaning and quality assurance as recommended by the manufacturer.
- 4.9 Detector signals must undergo routine amplification if required as well as standard image post processing.
- 4.10 Image signal-to-noise and detective quantum efficiency must meet or exceed current professional recommendations for chest radiography or manufacturer's specification, whichever is the most stringent.
- 4.11 If the facility does not allow horizontal positioning of the image detector, two side by side images can be used if they include all lung fields, both apices and costophrenic angles.

Image manipulation

- 4.12 Image management software and settings for routine chest imaging supplied by the image processing vendor must be used.
- 4.13 Image or edge enhancement functions **must not** be used or associated settings set to lowest possible on the imaging equipment.

Image data file

- 4.14 Image data file and associated transmission and storage must be in line with the current Digital Imaging and Communications in Medicine (DICOM[®]) standard. Reports should be prepared and retrievable in a format that is both readable and readily electronically

⁹ Capital Sensitivity program - <http://www.health.gov.au/capitalsensitivity>

transmissible so reports can be directly imported into Australian clinical information systems (e.g. HL7 format, PDF file format).

- 4.15 Data systems must have sufficient physical, technical and administrative controls to prevent unauthorised access to health data.
- 4.16 If data compression is performed it must be lossless.

5. Image acquisition

- 5.1 Images must be taken digitally at the source.

Beam lighting devices

- 5.2 Radiographic equipment must have a beam-limiting device used with the radiographic image examination which does not cause unexposed boundaries.
- 5.3 Post-image acquisitions such as “shutters” which simulate collimator limits and limit the size of the final image **must not** be used.

Equipment specifications

- 5.4 The distance from source or focal spot to digital detector should be at least 180cm.
- 5.5 The maximum exposure time should not exceed one-twentieth of a second except with subjects with chests over a 28cm postero-anterior (PA) dimension, in which the exposure may be increased to one tenth of a second (classifications are only performed on PA projections).
- 5.6 The minimum voltage recommended by the digital imaging system manufacturer should be used for chest radiography, preferably using high kV technique (up to 125kVp) and at least 90kVp while minimising radiation exposure.
- 5.7 Adhere to manufacturer’s guidelines on exposure for a standard PA chest radiograph.
- 5.8 A suitable grid (e.g. with a ratio of 12:1 or 14:1) or air gap for reducing scattered radiation is required; however special caution is advised in the selection of grids for use with digital systems so that image artefacts do not occur.
- 5.9 Image artefacts must not be in the horizontal or vertical image.
- 5.10 Equipment should be maintained to the equipment manufacturer’s specifications as per DIAS requirements and inspected in accordance with State or Territory regulations.

Image quality

- 5.11 Before the subject is advised that the examination is concluded, the radiographic image should be processed to an image file and inspected and accepted for quality by a radiologist or radiographer.
- 5.12 The practice must have evidence of documented and reviewed chest imaging protocol approved by the lead radiologist, lead radiographer and/or medical physicist.
- 5.13 The practice must have evidence of ongoing image quality review.

- 5.14 Images should be ILO quality 2 or better as determined by NIOSH approved B-Reader with fewer than 5 per cent graded technical quality 3 or 4 (refer to Part 2 for grading).

6. Documentation

- 6.1 Images must be stored as DICOM® Digital X-ray (DX) objects.
- 6.2 Identification of the image, patient, facility, date and time of the examination must be included in the file header according to the DICOM® standard format.
- 6.3 For auditing purposes, the radiographer responsible for performing the X-ray must note the exposure parameters (kVp, mA, time) and where possible, the beam filtration, scatter reduction and radiation exposure, on the image (or saved within the DICOM® file).

7. Quality assurance and control

- 7.1 The practice must implement a radiation Safety and Protection Plan or equivalent Radiation Management Plan as required by State or Territory licensing to ensure radiation dose is minimised.
- 7.2 Quality assurance testing must be performed periodically as recommended by the equipment manufacturers and suppliers and the results documented.
- 7.3 Additionally, quality control is to be carried out according to the RANZCR General X-ray QA and QC Guideline¹⁰, except with the frequencies indicated in the RANZCR Guidelines for Quality Control Testing for Digital (CR DR) Mammography¹¹ where there is an equivalent test.

¹⁰ RANZCR General X-ray QA and QC Guideline <https://www.ranzcr.com/search/?searchword=general+X-ray+qa+and+qc+guideline&ordering=relevance&direction=asc&limitstart=0>, accessed: 21 July 2017.

¹¹ RANZCR Guidelines for Quality Control Testing for Digital (CR DR) Mammography, <https://www.ranzcr.com/fellows/clinical-radiology/quality-assurance-and-accreditation/mqap>, accessed: 21 July 2017.

Part 2: Technical guidelines for taking chest X-rays

Grading images

The ILO Classification grades images from 1 to 4 with grade 1 images being the highest quality. A list of grading and explanation of the grading is provided below.

Table A: Technical grading

ILO grading	Technical grading
Grade 1: Good. Free of technical imperfections	-
Grade 2: Acceptable. Minor technical imperfections that do not impair classification of opacities.	Minor artefacts that are not projected over the heart or lungs
Grade 3: Technical defects or artefacts but still able to classify.	Minor under or over exposure that does not preclude assessment of opacities Minor unsharpness or motion Malposition that does not preclude assessment
Grade 4: Unacceptable	Incomplete imaging of the lungs Marked under or over exposure: unable to grade

If an image is not graded 1, a comment must be made about the technical defect on the ILO Classification form as shown in Image A¹².

Image A – ILO Classification form section 1

1. IMAGE QUALITY		<input checked="" type="checkbox"/> Overexposed (dark)	<input checked="" type="checkbox"/> Improper position	<input type="checkbox"/> Underinflation	<u>Scapula overlay</u>
<input type="checkbox"/> 1	<input checked="" type="checkbox"/> 2	<input type="checkbox"/> 3	<input type="checkbox"/> U/F	<input type="checkbox"/> Underexposed (light)	<input type="checkbox"/> Poor contrast
(If not Grade 1, mark all boxes that apply)		<input type="checkbox"/> Artifacts	<input type="checkbox"/> Poor processing	<input checked="" type="checkbox"/> Other (please specify)	_____

¹² Guidelines for the use of the ILO International Classification of Radiographs of Pneumoconioses (Revised Edition 2011), page 3.

Common difficulties

The common difficulties hindering the taking of a quality 1 image include scapula overlay, excessive edge enhancement and chest wall variations.

Scapula overlay

Many mine workers have rotator cuff issues or back problems and cannot completely rotate their scapula off the chest. Radiographers are to support the worker to rotate as much of the scapula as possible and note on the ILO Classification form the worker has problems rotating the scapula off.

Excessive edge enhancement

Edge enhancement should not be used where possible or reduced to the lowest setting when the equipment does not have a zero setting.

Chest wall variations

Dense breast tissue/large body habitus can result in reduced contrast penetration in the lower lobes compared to the upper lobes.

Examples of images and interpretation

Image 1 – Chest X-ray 1

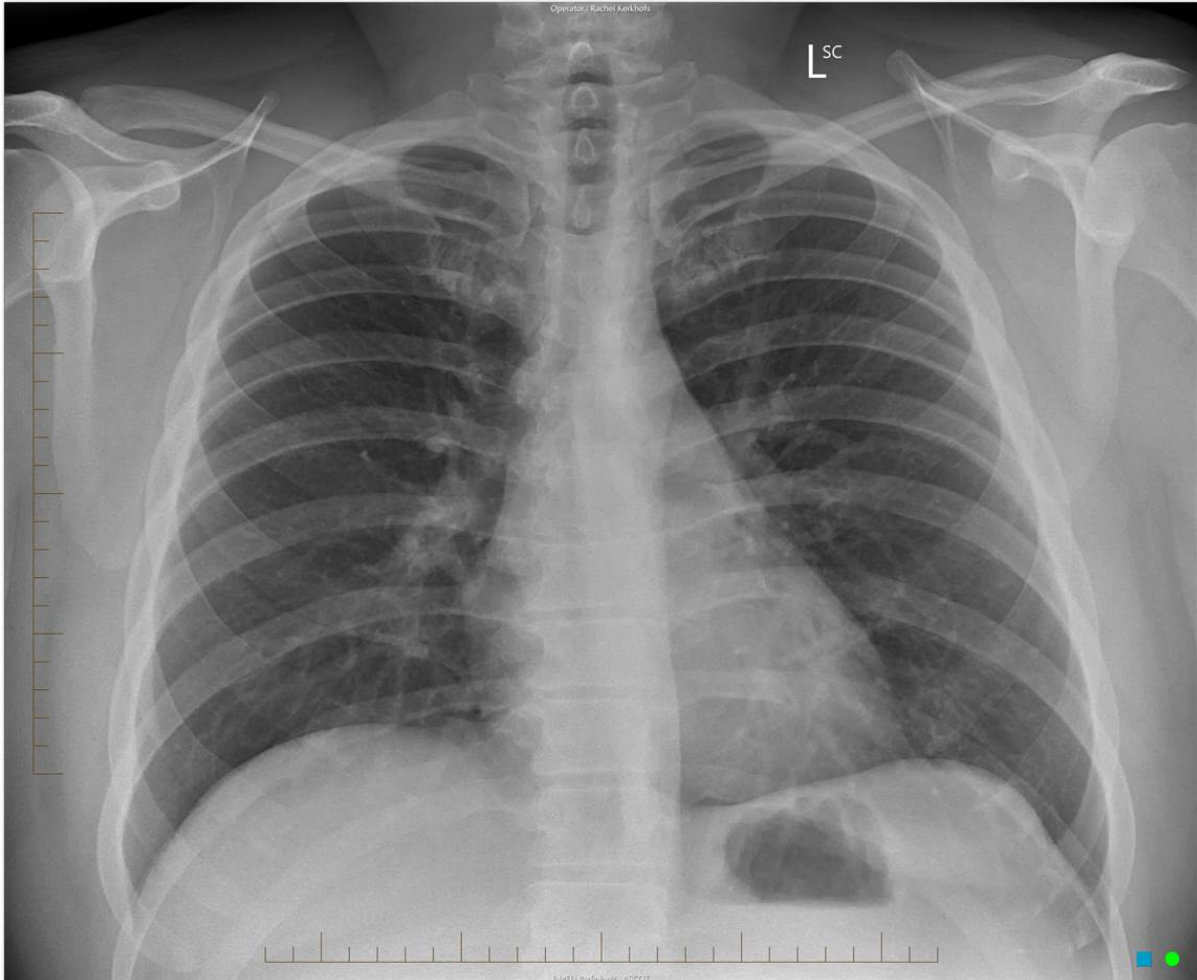


Table 1 – Interpretation of chest X-ray 1

Grading	1
Interpretation	Good penetration Outline of both hemidiaphragms seen Scapula off No edge enhancement

Image 2 – Chest X-ray 2

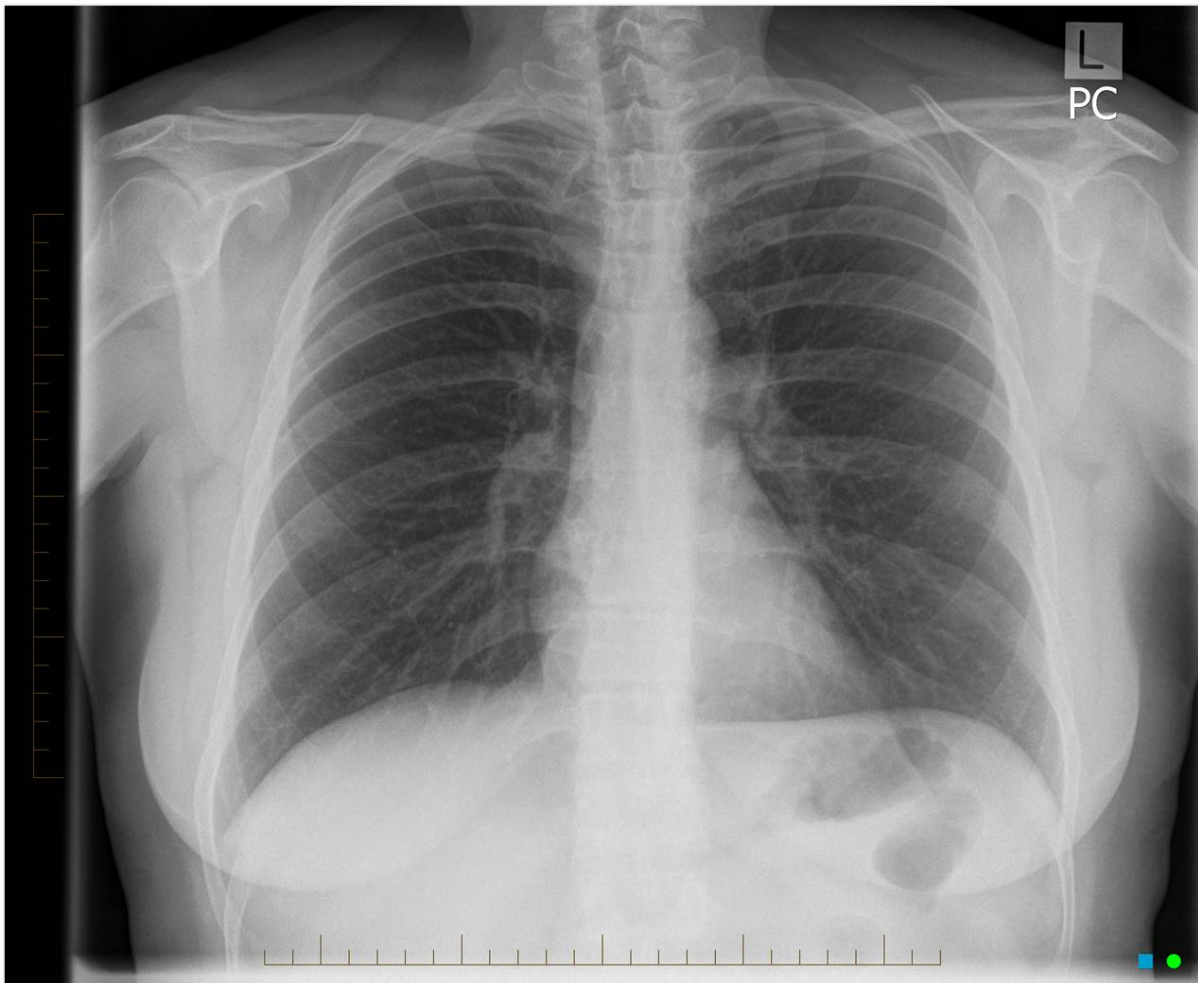


Table 2 – Interpretation of chest X-ray 2

Grading	1
Interpretation	Good penetration Scapula off No edge enhancement

Image 3 – Chest X-ray 3

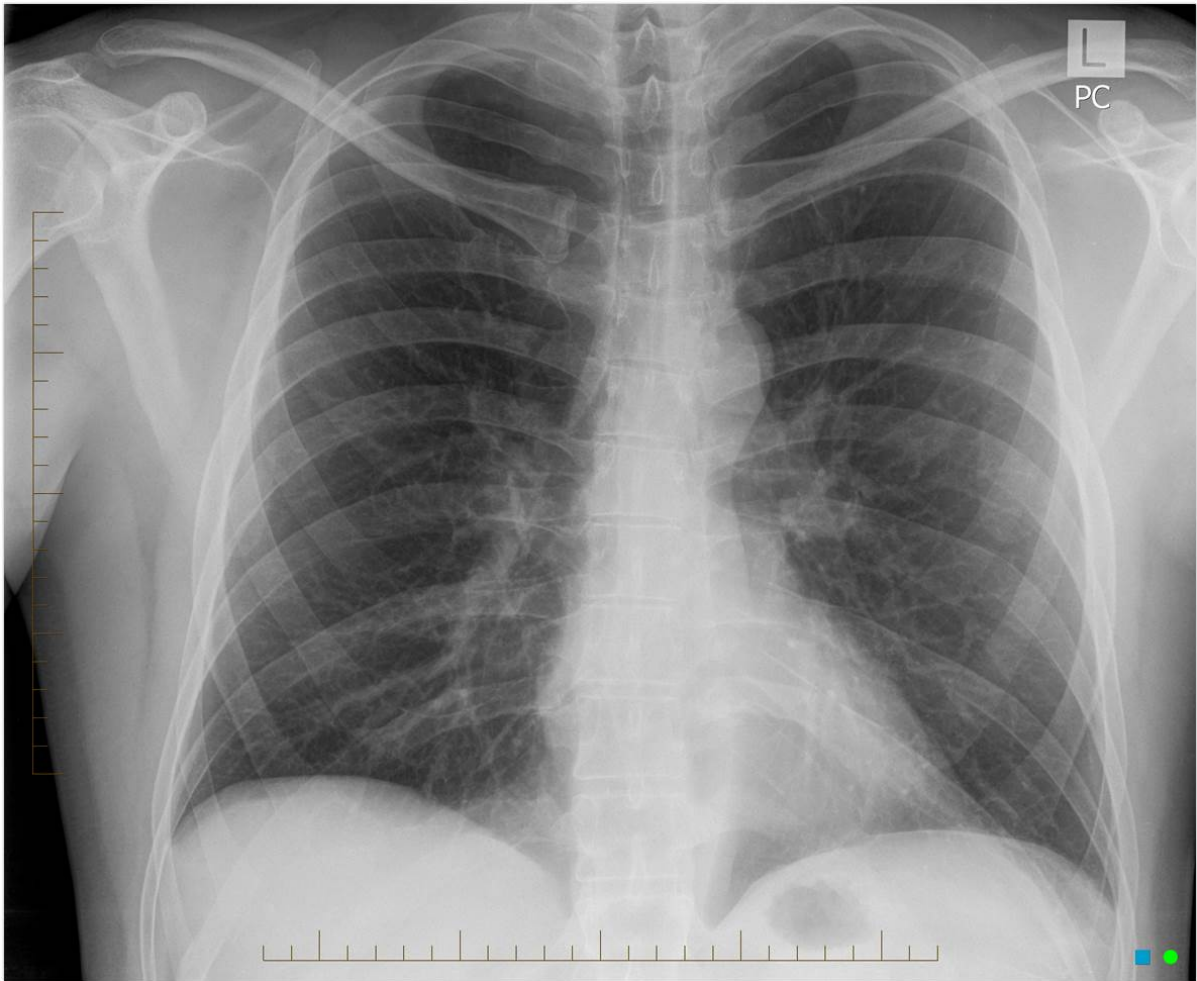


Table 3 - Interpretation of chest X-ray 3

Grading	2
Interpretation	Overexposed (dark) Improper position Minor scapula overlay
Note	Many miners have rotator cuff tears and have significant problems rotating the scapula off. If this is the case, radiographers should note this on the ILO Classification form.

Image 4 – Chest X-ray 4

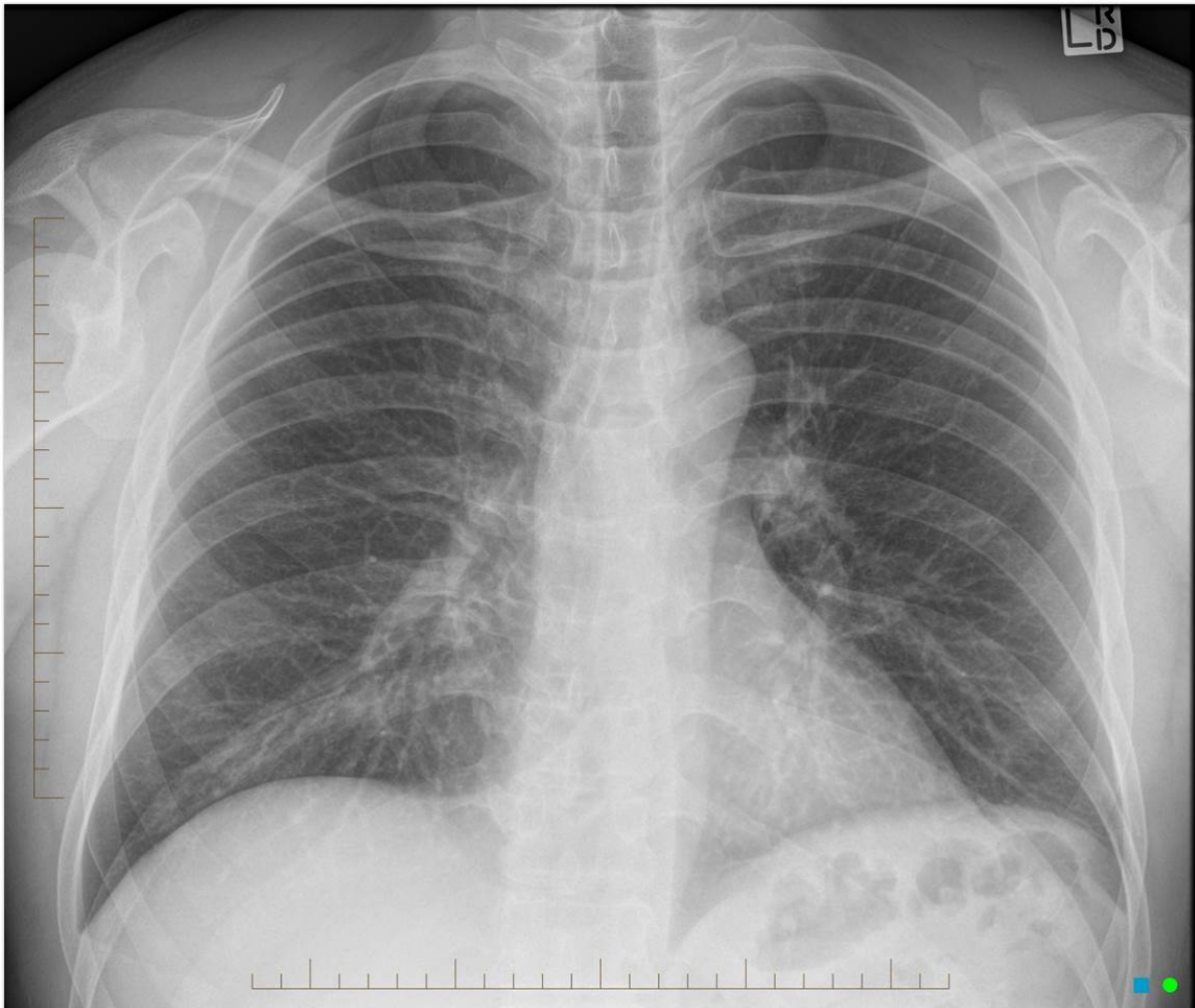


Table 4 - Interpretation of chest X-ray 4

Grading	2
Interpretation	Excessive edge enhancement End on vessels standout too much Easy to overcall as opacities

Image 5 – Chest X-ray 5

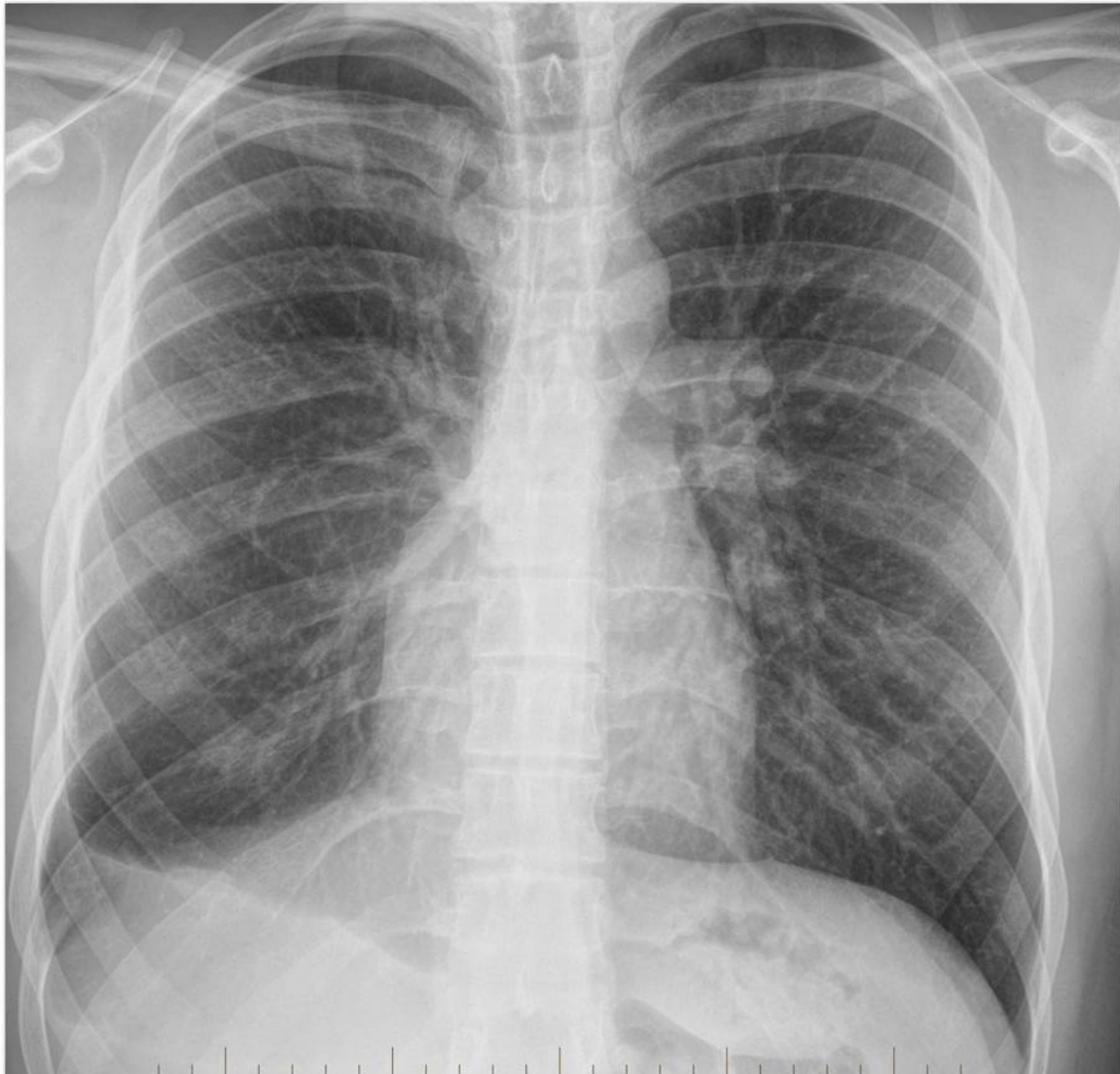

Table 5 - Interpretation of chest X-ray 5

Grading	3
Interpretation	Poor contrast Excessive edge enhancement Easy to overcall end on vessels as opacities
Note	Image 5a – CT scan confirms lungs are normal

Image 5a – CT scan

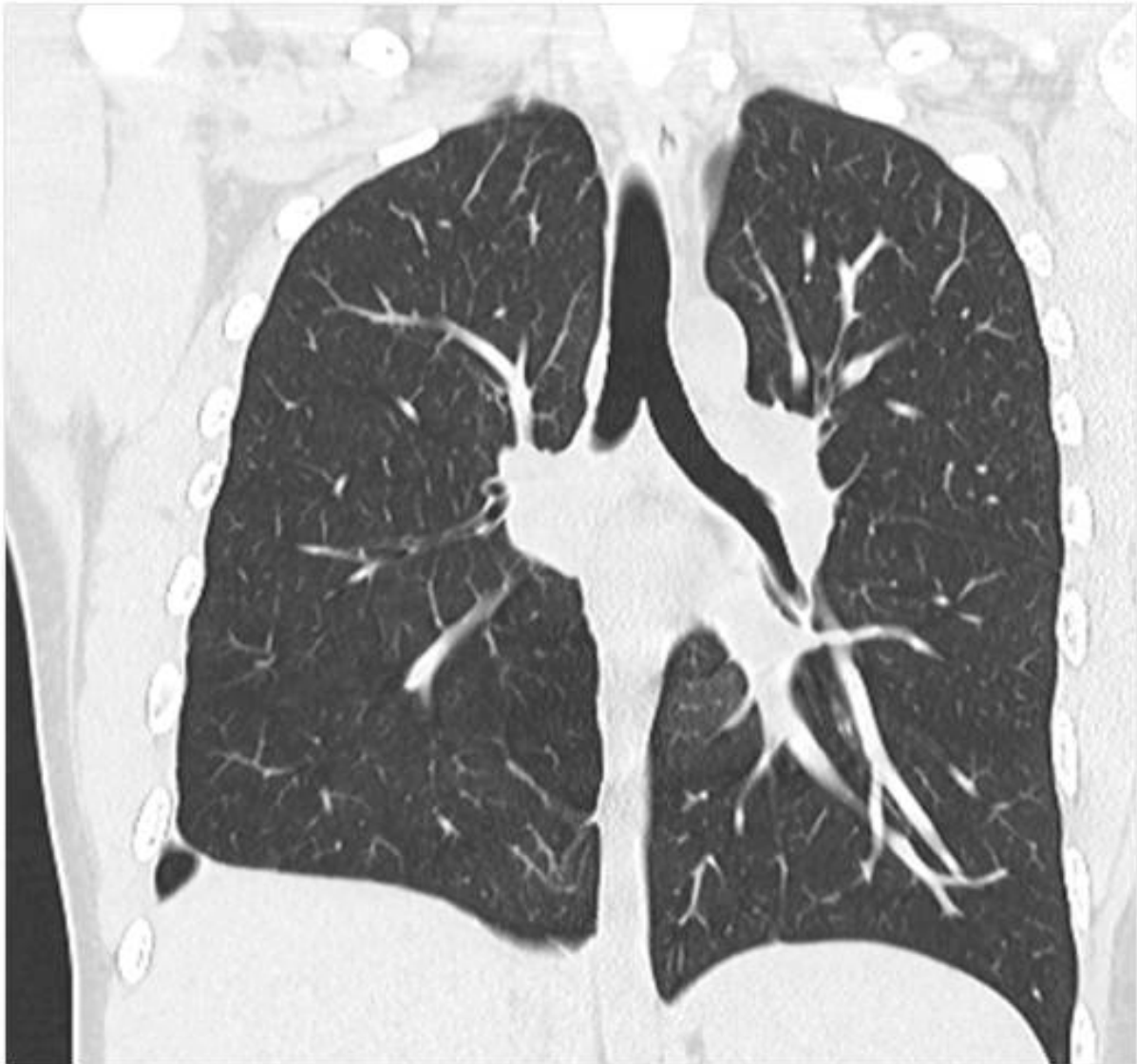


Image 6 – Chest X-ray 6

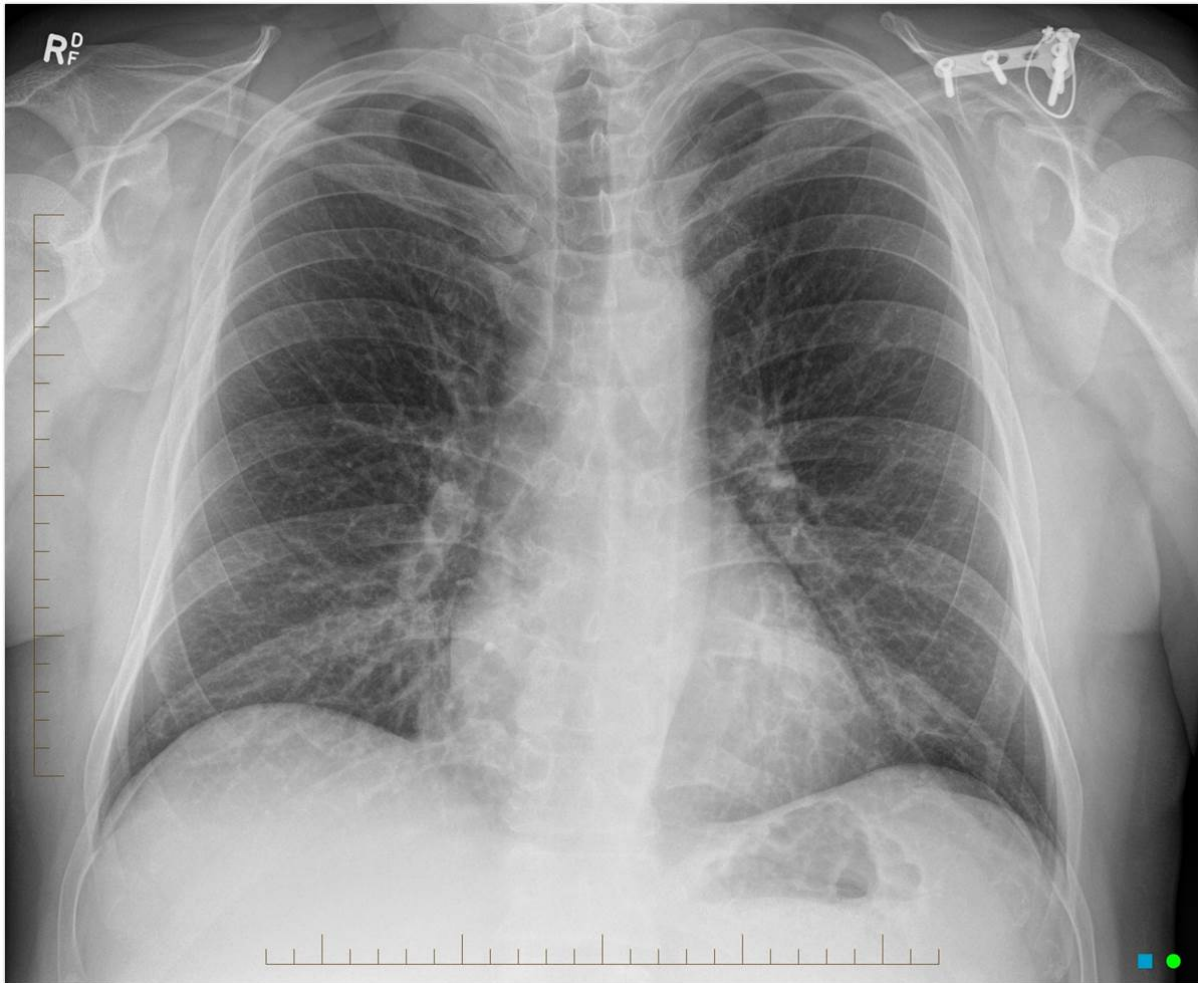


Table 6 - Interpretation of chest X-ray 6

Grading	3
Interpretation	Excessive edge enhancement Less marked than chest X-ray image 5

Image 7 – Chest X-ray 7

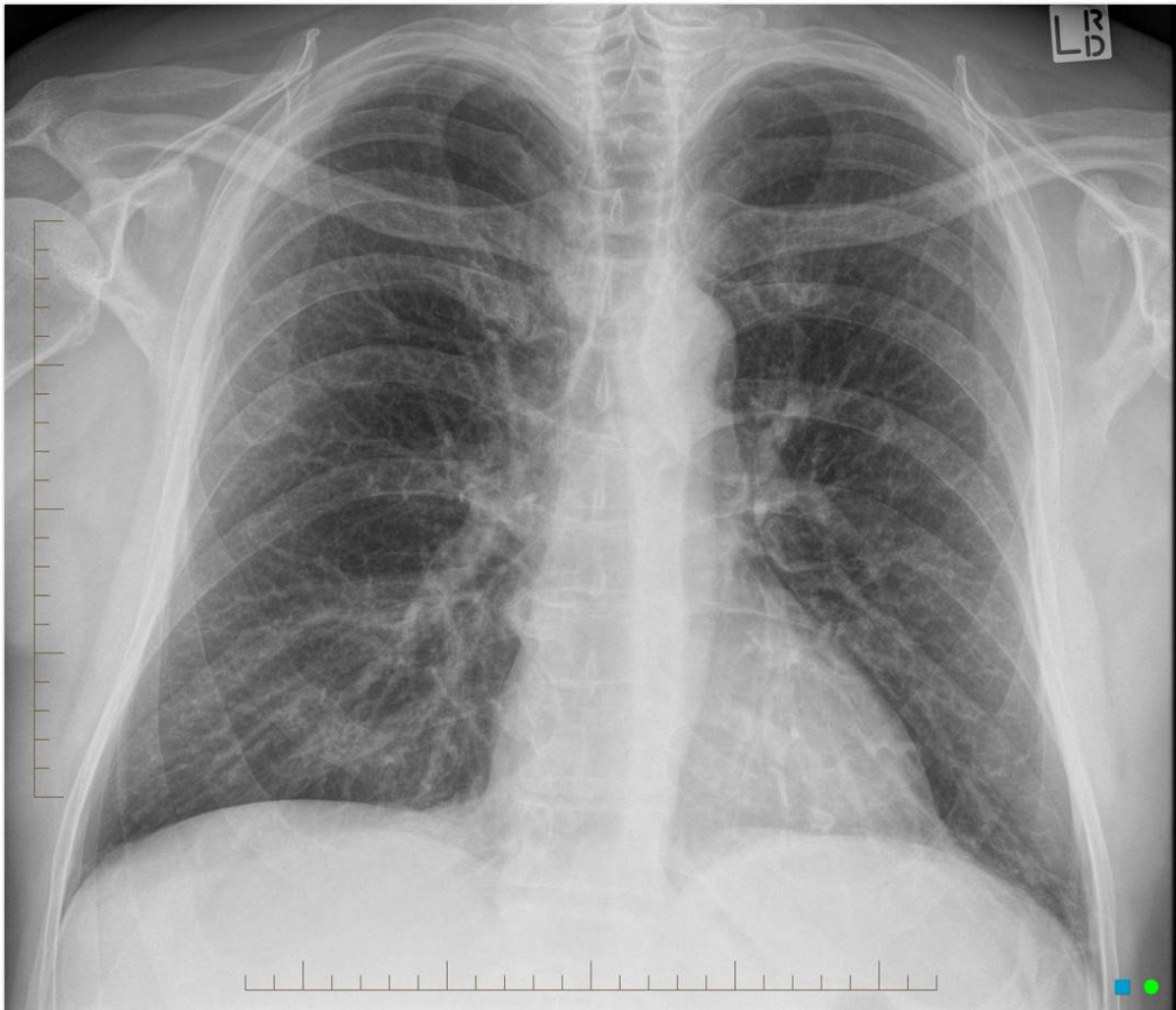


Table 7 - Interpretation of chest X-ray 7

Grading	3
Interpretation	Improper position Poor contrast Excessive edge enhancement and scapula overlay
Note	Consider repeat

Image 8 – Chest X-ray 8

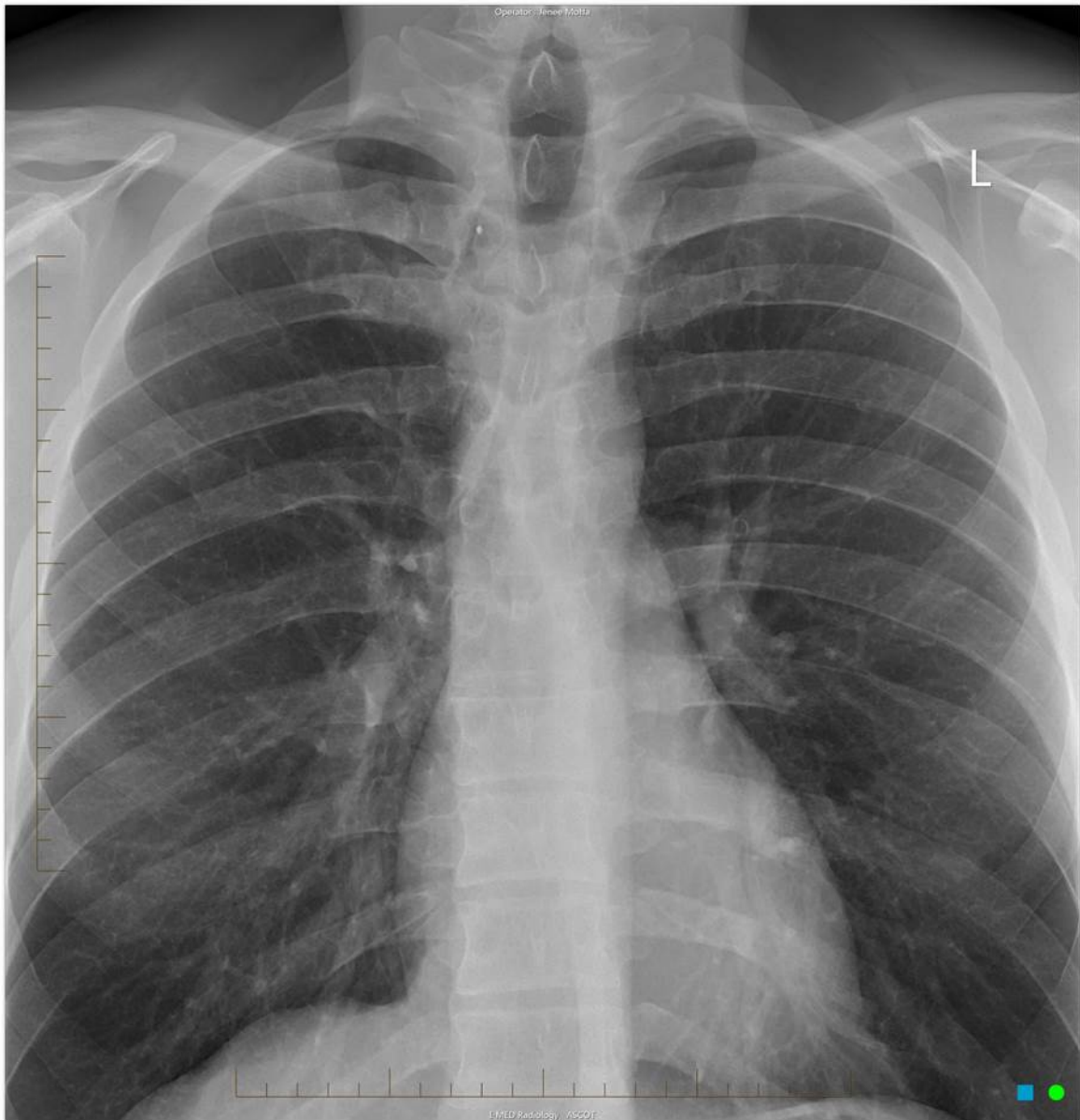


Table 8 - Interpretation of chest X-ray 8

Grading	3
Interpretation	Improper positioning Costophrenic angles and lateral chest cut off
Note	Repeat

Image 9 – Chest X-ray 9¹³

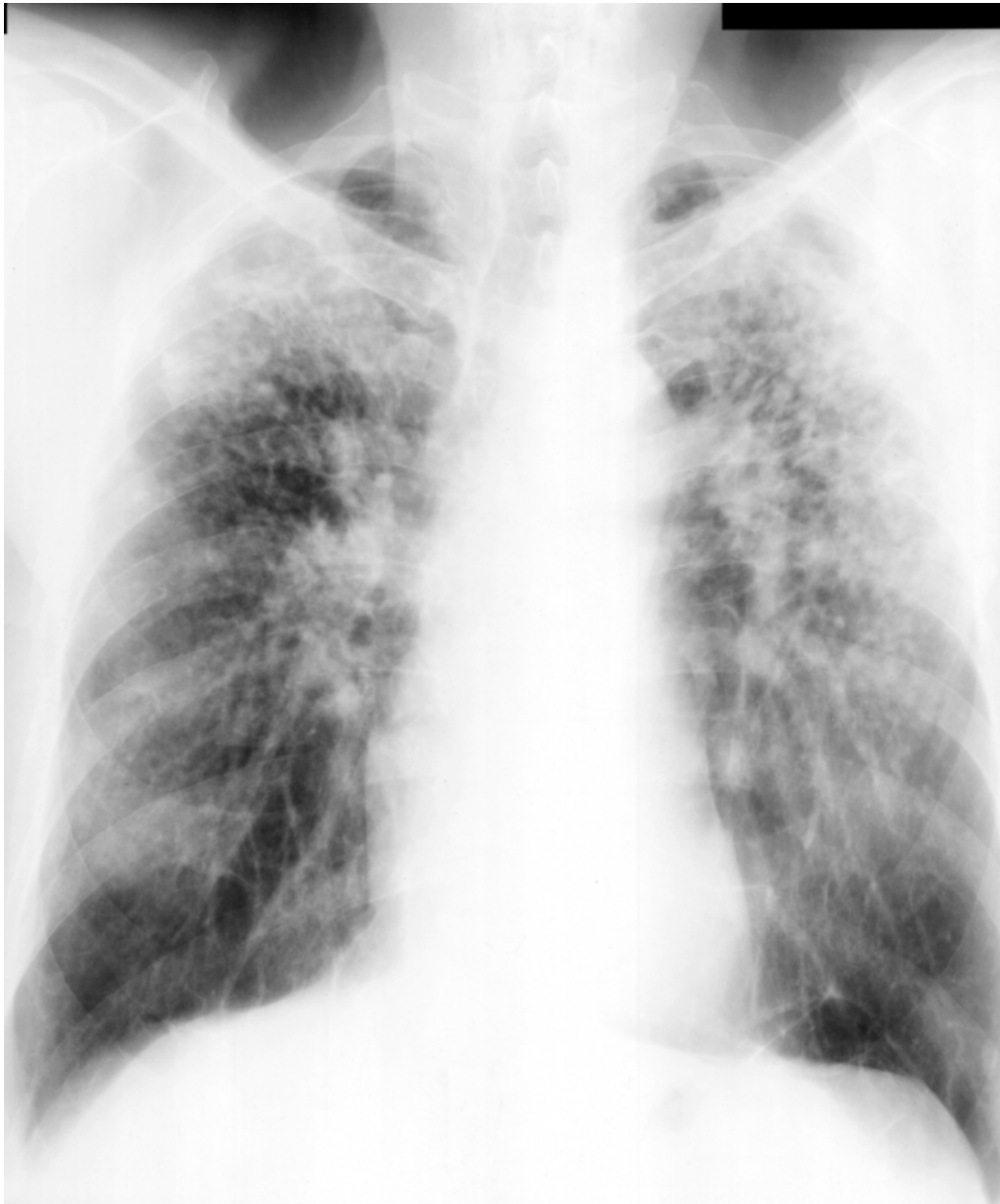

Table 9 - Interpretation of chest X-ray 9

Grading	3
Interpretation	Underexposed (light)

¹³ US Center for Disease Control and Prevention, National Institute for Occupational Safety and Health (NIOSH) B Reader Study Syllabus for Classification of Radiographs of Pneumoconiosis 2000 Revision. Accessed 23 May 2017 from <https://www.cdc.gov/niosh/topics/chestradiography/breader-study-syllabus.html>

Image 10 – Chest X-ray 10¹⁴

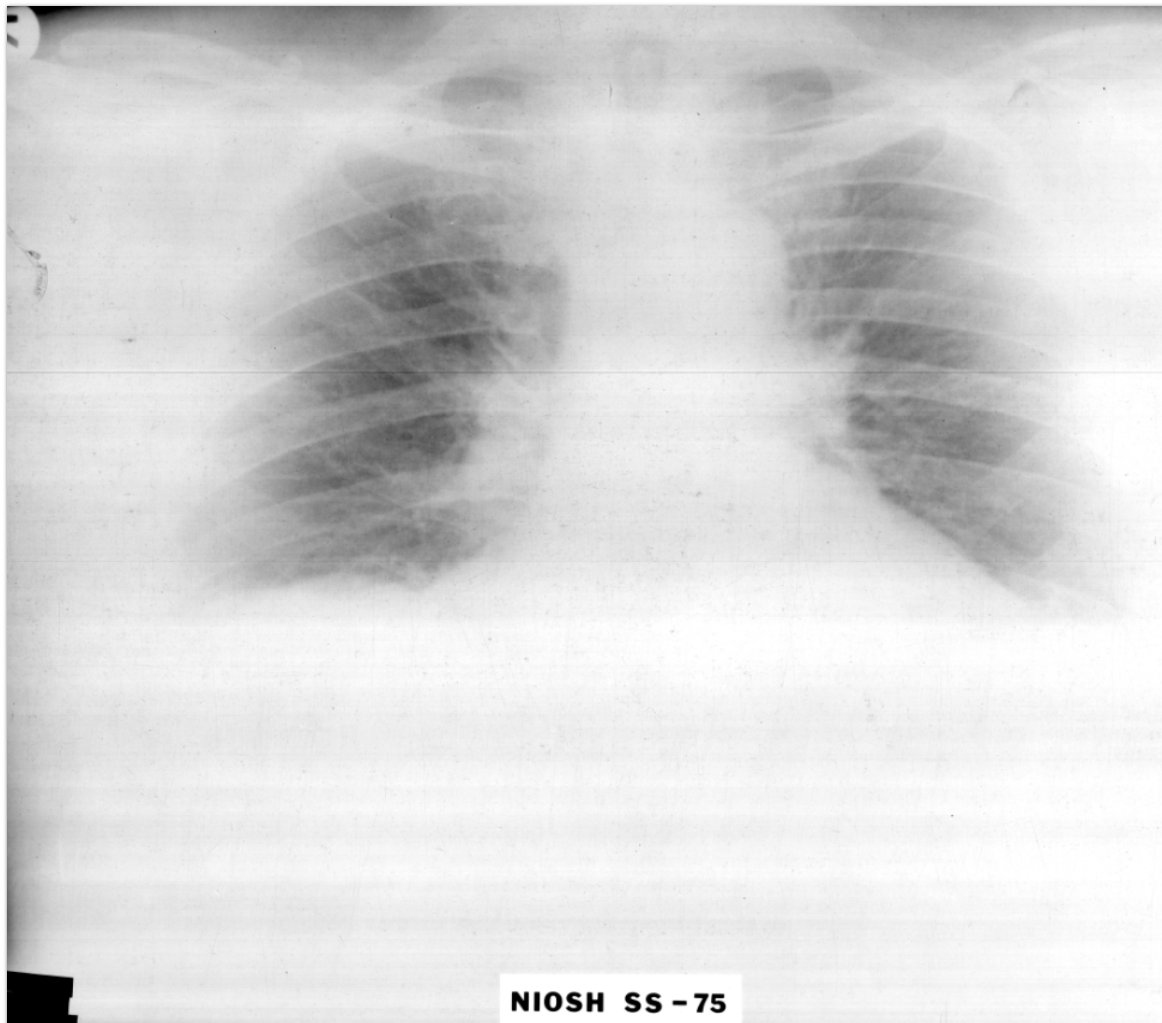


Table 10 - Interpretation of chest X-ray 10

Grading	4
Interpretation	Badly underexposed The presence of absence of pneumoconiosis cannot be determined.

¹⁴ US Center for Disease Control and Prevention

References

- Department of Health. (2016, January 1). *Diagnostic Imaging Accreditation Scheme Practice Accreditation Standards*. Retrieved July 17, 2017, from [http://www.health.gov.au/internet/main/publishing.nsf/Content/DCC9E1DB6C39C2CFCA257E92000AE255/\\$File/Practice%20Accreditation%20Standards%20-%20from%201%20January%202016.pdf](http://www.health.gov.au/internet/main/publishing.nsf/Content/DCC9E1DB6C39C2CFCA257E92000AE255/$File/Practice%20Accreditation%20Standards%20-%20from%201%20January%202016.pdf)
- Department of Health, Australian Government. (2017, March 23). *Equipment, Medicare and diagnostic imaging*. Retrieved June 30, 2017, from <http://www.health.gov.au/capitalsensitivity>
- International Labour Organization. (2011). *Guidelines for the use of the ILO International Classification of Radiographs of Pneumoconioses Revised edition 2011*. Retrieved July 17, 2017, from http://www.ilo.org/wcmsp5/groups/public/---ed_protect/---protrav/---safework/documents/publication/wcms_168260.pdf
- Monash University and the University of Illinois at Chicago. (2016, July 12). *Review of the Respiratory Component of the Coal Mine Workers' Health Scheme for the Queensland Department of Natural Resources and Mines Final Report*. Retrieved July 17, 2017, from https://www.dnrm.qld.gov.au/__data/assets/pdf_file/0009/383940/monash-qcwp-final-report-2016.pdf
- National Institute for Occupational Safety and Health. (2011, August). *NIOSH Guideline Application of Digital Radiography for the Detection and Classification of Pneumoconiosis*. Retrieved July 17, 2017, from <https://www.cdc.gov/niosh/docs/2011-198/default.html>
- The Royal Australian and New Zealand College of Radiologists. (2013, November 15). *General X-ray QA and QC Guideline*. Retrieved July 17, 2017, from <https://www.ranzcr.com/search/?searchword=general+X-ray+qa+and+qc+guideline&ordering=relevance&direction=asc&limitstart=0>
- The Royal Australian and New Zealand College of Radiologists. (2017, March 20). *Standards of Practice for Diagnostic and Interventional Radiology, Version 10.2*. Retrieved July 17, 2017, from <https://www.ranzcr.com/search?searchword=standard+of+practice>
- US Centre for Disease Control and Prevention. (n.d.). *National Institute for Occupational Safety and Health (NIOSH) B Reader Study Syllabus for Classification of Radiographs of Pneumoconiosis 2000 Revision*. Retrieved May 23, 2017, from <https://www.cdc.gov/niosh/topics/chestradiography/breader-study-syllabus.html>